

affinity

ADVANCE
VETERINARY DIETS

Research reports

A RESEARCH UPDATE
FOR VETERINARY SURGEONS
FROM AFFINITY PETCARE

FELINE ATOPIC SYNDROME

^aRamón Almela, PhD in Veterinary Medicine, Dip. ECVD

^bIsabelle Jeusette, PhD in Veterinary Medicine

^cLluís Vilaseca, MSc in Veterinary Medicine

^a Cummings School of Veterinary Medicine,
Tufts University, N. Grafton, MA, USA

^b Research, Affinity Petcare, Barcelona

INTRODUCTION

Skin allergies are currently one of the most common diseases in dogs and cats seen in daily veterinary practice. In 2015, the existing knowledge of skin allergies in dogs was updated when a group of experts published a series of monographs on the subject. However, until recently nothing similar had been published about cats, due mainly to the lack of in-depth research and clinical studies (Moriello 2021).

In cats, the various allergic diseases differ depending on pathogenesis, thus impacting nomenclature, clinical phenotypes, diagnostic algorithms and treatment. The prevalence of these allergic diseases has not been clearly established due to inconsistencies in the currently available data and the hetero-



generality of clinical studies. To date, no conclusive evidence has been published on the genetic basis and the role of immunoglobulin E (IgE) in cats (Halliwell 2021), two factors that define diseases and individuals as *atopic*. However, they share certain common elements with dogs and people.

All these limitations notwithstanding, the term **feline atopic syndrome** has been proposed to cover various allergic diseases caused by environmental and food allergens and asthma, with two important exceptions for diseases caused by insects: hypersensitivity to mosquito bites, and flea allergy dermatitis, even though these pathologies may contribute to or present as a clinical phenotype that is similar to feline atopic syndrome.

As a subgroup within *feline atopic syndrome*, the term **feline atopic skin syndrome (FASS)** has been proposed for the skin disease which can be associated with the development of IgE antibodies in the presence of environmental allergens (Figure 1).

Food allergies (or adverse food reactions) and flea allergy dermatitis can also contribute to or present clinical phenotypes similar to *feline atopic skin syndrome* (Halliwell 2021).

PATHOGENESIS

Information on pathogenic mechanisms in *feline atopic syndrome* is currently rather sparse. Allergic diseases tend to have a genetic basis (genetically predisposed individuals who display an anomalous immune response to certain harmless environmental and/or food allergens) and an impaired epidermal barrier associated with the effect of various environmental factors such as lifestyle, diet, exposure to chemicals, climate, etc. (Figure 2).

Demographic data are not well established, but studies show that it is a disease that appears particularly in young cats under three years of age and is more prevalent in females and

FIGURE 1. Allergic diseases included in feline atopic syndrome

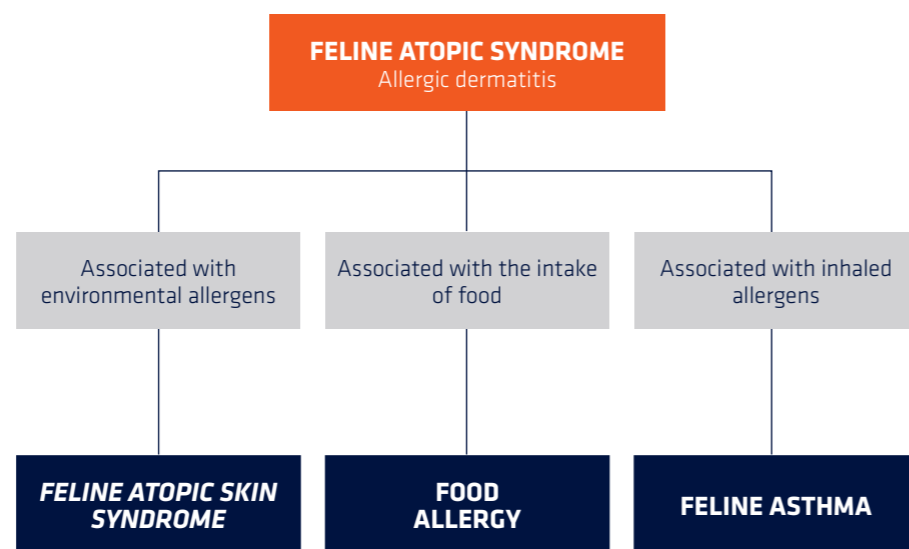
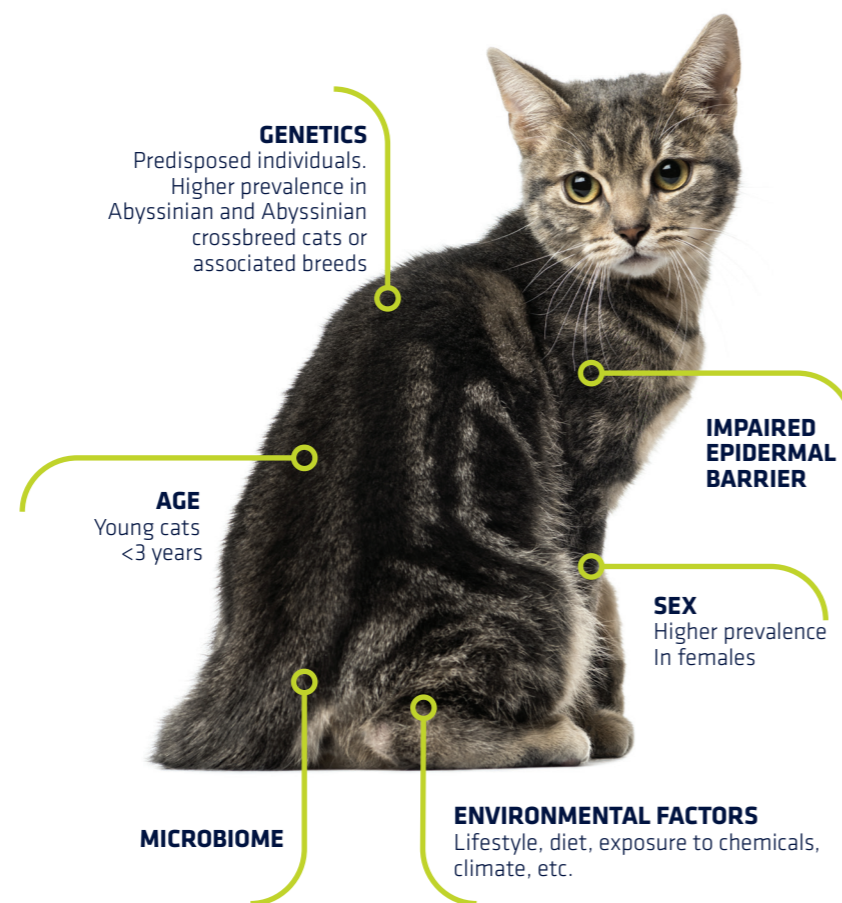


FIGURE 2. Factors affecting the appearance of feline atopic syndrome



CHARACTERISTICS OF THE VARIOUS ALLERGIC DISEASES IN CATS DIFFER DEPENDING ON PATHOGENESIS, THUS IMPACTING NOMENCLATURE, CLINICAL PHENOTYPES, DIAGNOSTIC ALGORITHM AND TREATMENT.

Abyssinian or Abyssinian crossbreed cats and associated breeds (Figure 2).

Another factor recently identified as possibly playing a role in the development of skin allergies in dogs and also in people is the microbiome.

It is likely that all these factors play a role in feline allergies. However, they have not been identified and characterised as thoroughly as in dogs and humans. Further research and clinical studies on the subject are needed to bolster what evidence there is. Neither genetic predisposition nor epidermal barrier impairment have been consistently identified in allergic cats. The few studies carried out to evaluate the skin microbiome in allergic cats indicate that, unlike the situation in dogs and humans, the composition of bacterial communities is similar in both healthy cats and allergic cats (Older 2021).

In allergic cats, the **immune response** is not as well defined as in dogs. On the one hand, there is evidence pointing to the development and involvement of IgE antibodies in some allergic cats. One such example is provided by studies showing positive results in allergen tests (whether intradermal or serological), with clinical improvement following allergen-specific immunotherapy. Factors implying that these antibodies do not necessarily play a significant role in *feline atopic skin syndrome* include:

- the recent determination of **concentration thresholds** for different allergens designed to avoid irritation on intradermal testing,
- the **lack of data** supporting the validity and reliability of some serological tests,
- the **inexistence of studies** in cats of similar ages in both control and allergic groups (this aspect is important, since serum IgE levels in cats rise with age).

The first thing to bear in mind is that, as with dogs, no significant differences have been found in serum IgE levels between healthy and atopic individuals, and that there can be cross-reactions between dust mite allergens and those of certain helminths.

The second point is that, just like in people and dogs, some allergic cats may exhibit an intrinsic allergy, with IgE antibodies whose presence is not proven by intradermal or serological testing (Halliwell 2021).

In addition to IgE antibodies, another aspect of the anomalous immune response in *feline atopic skin syndrome* is the identification of the various types of **immunity cells, immune responses, cytokines** and expressed **growth factors** involved. To date, few studies have investigated immunopathology in allergic cats. Studies characterising cells in histological samples taken from cats diagnosed with *feline atopic syndrome* have shown that the inflammatory infiltrate consists mainly of mastocytes, eosinophils, CD4 T-cells, Langerhans cells, dermal dendritic cells and, to a lesser degree, immunoglobulin-secreting plasma cells.

In these studies, a greater number of inflammatory cells were found in damaged skin than in skin free of macroscopic lesions. They were also found in greater numbers in allergic cats than in healthy cats (Halliwell 2021).

In terms of the type of **immune response** and **associated cytokines**, firstly it would appear that there is a systemic inflammatory response, given the increased serum levels of some of these cytokines (Vargo 2021). These cytokines and growth factors that were found in increased numbers are associated with a Th1- and Th2-type immune response. In any event, the main limitation of studies undertaken so far on the immunopathology of *feline atopic syndrome* is that very few have been published in very few animals, and they were very heterogeneous in terms of clinical presentation, age and breed of the allergic cats used as subjects. Food allergies are thought to have an immunopathological basis which may involve type I and type IV hypersensitivity reactions.

CLINICAL SIGNS

In contrast to dogs and people, clinical manifestation in cats is highly variable.

Feline atopic syndrome covers various allergic diseases that affect the **skin** (*feline atopic skin syndrome* or *FASS*), the **respiratory system** (feline asthma) and the **gastrointestinal system** (feline food allergy).

» SKIN SIGNS

These include four reaction patterns that can develop singly or in combination with others, and do not necessarily involve pruritus. These patterns of skin reaction seen in cats are not specific to a particular disease, although they may often be associated with *feline atopic skin syndrome* (*FASS*) and feline food allergy (Diesel 2020). These patterns are: **miliary dermatitis**, **self-inflicted alopecia / hypotrichosis**, **cervico-facial pruritus**, and lastly, the **eosinophilic granuloma complex** (Santoro 2021).

Eosinophilic granuloma complex includes several clinical syndromes such as **indolent ulcer** (or *rodent ulcer*) which appears on the upper lips (Image 1), or **eosinophilic granuloma** which can develop on the back legs, especially the

thighs, and is linear in nature, or in the area of the chin (*fat chin*) and even in the oral cavity (**Images 2 and 3**). The third clinical syndrome is **eosinophilic plaque** which, although more prevalent on the ventral abdominal region and on the thighs, may also develop in other areas of the body (**Image 4**). The presence of pruritus is variable in these eosinophilic syndromes, although it is seen more frequently in eosinophilic plaque and rarely in indolent ulcers.

Miliary dermatitis appears as multiple small papules, often associated with scabs that may be localised in one area or disseminated all over the body, with or without pruritus (**Images 5 and 6**).

Self-inflicted alopecia / hypotrichosis is another cutaneous reactive pattern characterised by the development of alopecic or hypotrichotic areas, commonly on the ventral abdomen, limbs and/or back, due to excessive grooming. Such behaviour in cats tends to be related to pruritus (**Images 7 and 8**). The cat licks and gnaws at these areas, pulling out its fur and leading to alopecia or hypotrichosis. Some owners see excess grooming as a sign of stress, rather than associating it with pruritus.

However, relevant studies suggest that this behaviour is rarely associated with stress, in which case it would be known as **feline psychogenic alopecia**. It is possible that feline psychogenic alopecia is overdiagnosed; most cases are likely to be examples of *feline atopic syndrome*.

In other cases, cats exhibit this excessive grooming behaviour when out of sight of their human family. In any event, this manifestation of pruritus

THESE SKIN REACTION PATTERNS IN CATS ARE NOT SPECIFIC TO A PARTICULAR DISEASE.

IMAGE 1. Indolent ulcer with deep ulcer, fibrosis and facial deformation in upper lips and nasal planum

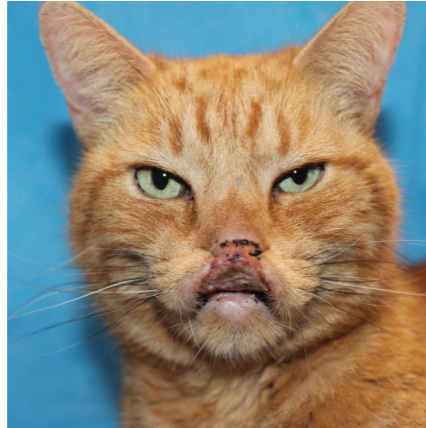

IMAGE 2. *Fat chin* or chin eosinophilic granuloma

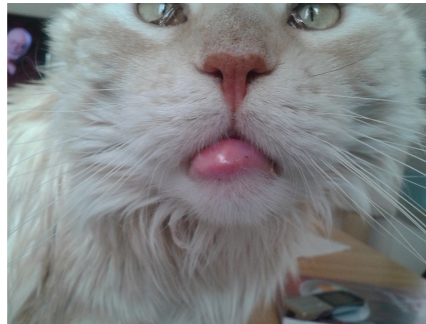


IMAGE 3. Granulomas of various sizes in the oral cavity of a cat with *feline atopic skin syndrome*

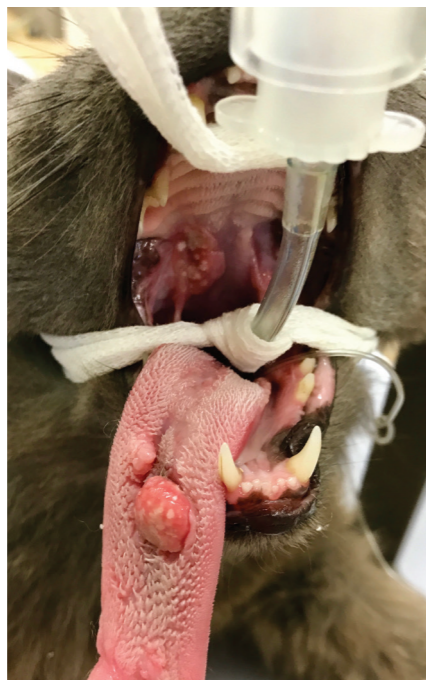

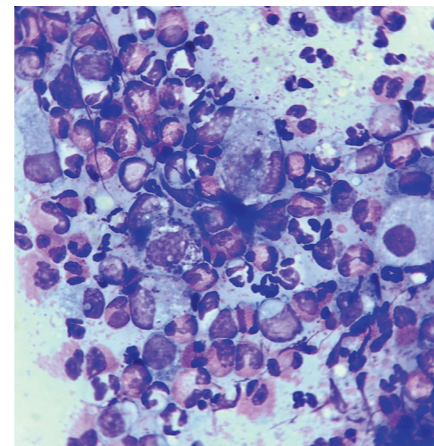
IMAGE 4. Eosinophilic plaques on the ventral abdomen

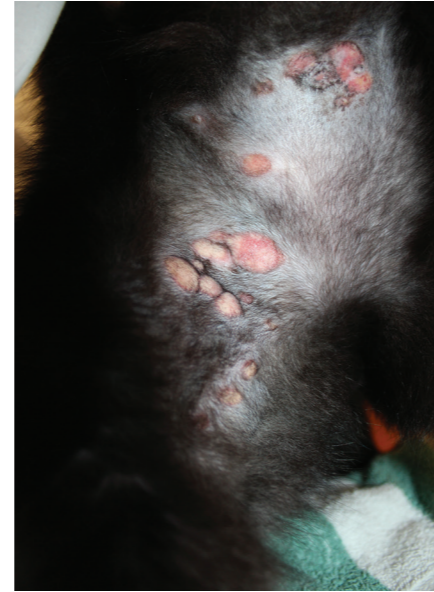

IMAGE 5. Miliary dermatitis in the preauricular area

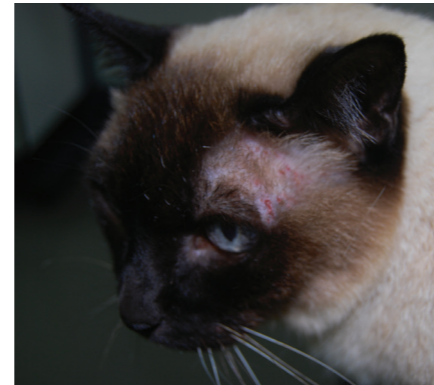

IMAGE 6. Cytology of a scab on a cat with miliary dermatitis due to skin allergy, showing numerous eosinophils



can be indirectly assessed by asking whether there is excess hair in the cat's faeces or any vomiting of hairballs. A trichogram or trichoscopy can also be done to check for broken hairs, which could be a sign of trauma due to licking (**Image 9**). Some products used for monitoring itching in dogs could even be used.

Cervico-facial pruritus (or pruritus of the head and neck) is characterised by usually severe pruritus in the region of the head and/or neck (Santoro 2021). This pruritus is so intense that cats harm themselves and lesions appear, such as excoriations, erosions and ulcers with differing degrees of severity (**Image 10**).

Otitis and pododermatitis, also included in *feline atopic syndrome*, are less frequent than canine atopic dermatitis. Other clinical signs that may appear in *feline atopic skin syndrome* and are not related to the skin include **ocular signs** (conjunctivitis) and signs associated with the respiratory and/or gastrointestinal tract.

» **RESPIRATORY SIGNS**

Respiratory signs include feline asthma and sneezing.

» **GASTROINTESTINAL SIGNS**

Gastrointestinal signs include vomiting, flatulence, diarrhoea, loss of appetite, or weight loss,

Other clinical signs associated with feline food allergy can be urticaria, the appearance of non-pruriginous nodules (one published case), and plasma cell pododermatitis (in six published cases) (Santoro 2021).

In general, it seems that non-cutaneous clinical signs are unusual, although their true prevalence is unknown.

IMAGE 7. Self-inflicted dorsal alopecia in an allergic cat

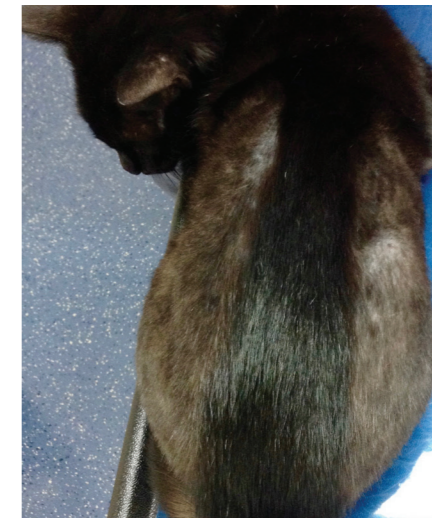

IMAGE 8. Self-inflicted alopecia on the ventral abdomen

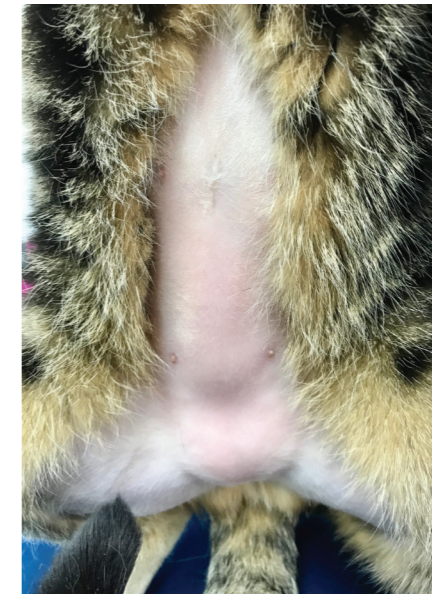


IMAGE 9. Trichoscopic examination of a pruritic cat with broken hairs as a result of trauma due to licking

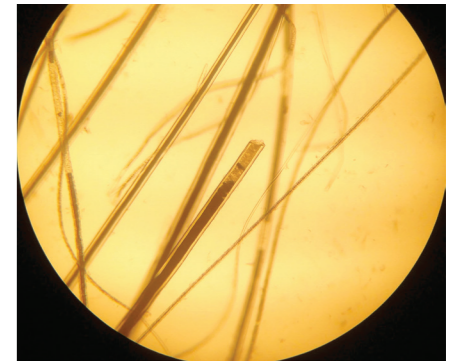
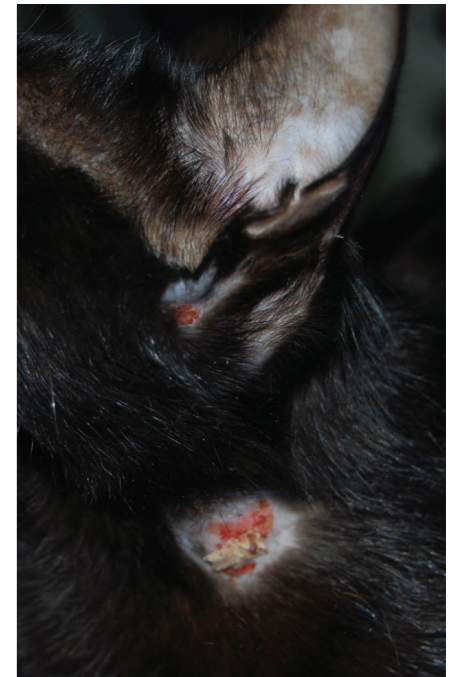

IMAGE 10. Ulcers on the neck area of an allergic cat due to severe cervico-facial pruritus



DIAGNOSTIC ALGORITHM

Diagnosis of *feline atopic skin syndrome* is a clinical diagnosis based on clinical history, results of physical and dermatological examination and the exclusion of relevant differential diagnoses (Tables 1-4).

Three factors are important in diagnostic and therapeutic processes:

- I) CONTROL OF ECTOPARASITES
- II) RULING OUT FOOD ALLERGIES
- III) IDENTIFICATION OF SECONDARY INFECTIONS

First of all, just like in dogs, food allergy in cats may be associated with an identical clinical skin phenotype. For the time being, an **elimination and provocation diet** is the **only diagnostic test available** for ruling out or confirming a food allergy, and is therefore necessary to reach a diagnosis of *feline atopic skin syndrome* (Figure 3). It is equally important to rule out flea allergy dermatitis and other diseases triggered by ectoparasites which may lead to pruritus or dermatitis such as lice, *Demodex gato*, *Notoedres cati*, *Cheyletiella blakei*, *Otodectes cynotis*, or dust mites of the Trombiculidae family (*Neotrombicula/Eutrombicula, Walbachia*).

Should ectoparasites (including fleas and flea allergy dermatitis) be suspected but not found in diagnostic tests (e.g. superficial skin scrapings, acetate

FOR THE TIME BEING, **ELIMINATION AND PROVOCATION DIET IS THE ONLY DIAGNOSTIC TEST AVAILABLE FOR RULING OUT OR CONFIRMING A FOOD ALLERGY.**

TABLE 1. Differential diagnoses in feline miliary dermatitis

SKIN REACTION PATTERN	MAIN DIFFERENTIAL DIAGNOSIS
Miliary dermatitis	Flea allergy dermatitis / Fleas
	Food allergy
	Dermatophytosis
	Bacterial folliculitis
	Ectoparasites (<i>Otodectes, Cheyletiella</i>)
	Pemphigus foliaceus
Drug eruption	

TABLE 2. Differential diagnoses in feline self-inflicted alopecia

SKIN REACTION PATTERN	MAIN DIFFERENTIAL DIAGNOSIS
Self-inflicted alopecia	Flea allergy dermatitis / Fleas
	Food allergy
	Dermatophytosis
	<i>Malassezia</i> dermatitis
	Ectoparasites (<i>Demodex gato</i>)
	Psychogenic alopecia
	Lower urinary tract disease

TABLE 3. Differential diagnoses in feline cervico-facial pruritus

SKIN REACTION PATTERN	MAIN DIFFERENTIAL DIAGNOSIS
Cervico-facial pruritus	Flea allergy dermatitis / Fleas
	Food allergy
	Dermatophytosis
	Pyoderma (deep/superficial)
	Ectoparasites (<i>Otodectes, Demodex gato</i> , <i>Notoedres</i>)
	Pemphigus foliaceus
	<i>Malassezia</i> dermatitis
	Adverse drug reactions (e.g., methimazole, also includes Spot On)
	Viral diseases (herpesvirus, papillomavirus, calicivirus, poxvirus, feline leukaemia virus)
	Neoplasia (cutaneous lymphoma, mastocytoma, squamous cell carcinoma)
	Primary hypoparathyroidism

TABLE 4. Differential diagnoses in feline eosinophilic granuloma complex

SKIN REACTION PATTERN	MAIN DIFFERENTIAL DIAGNOSIS
Feline eosinophilic granuloma complex	Flea allergy dermatitis / Fleas
	Food allergy
	Nocardiosis
	Mycobacteriosis
	Deep pyoderma
	Ectoparasites (<i>Otodectes, Cheyletiella</i>)
	Mycosis (e.g., sporotrichosis)
	Viral diseases (herpesvirus, papillomavirus, calicivirus, poxvirus, feline leukaemia virus)
	Neoplasia (cutaneous lymphoma, mastocytoma, squamous cell carcinoma)
	Sterile granulomatous diseases (e.g., xanthomatosis)

tape cytology, combing), an empirical treatment with antiparasitics is recommended in order to rule them out (Diesel 2020).

As can be seen in the tables showing the various differential diagnoses, flea allergy dermatitis and food allergy must be excluded as, in contrast to dogs, they can produce the same skin reaction patterns as *feline atopic skin syndrome*.

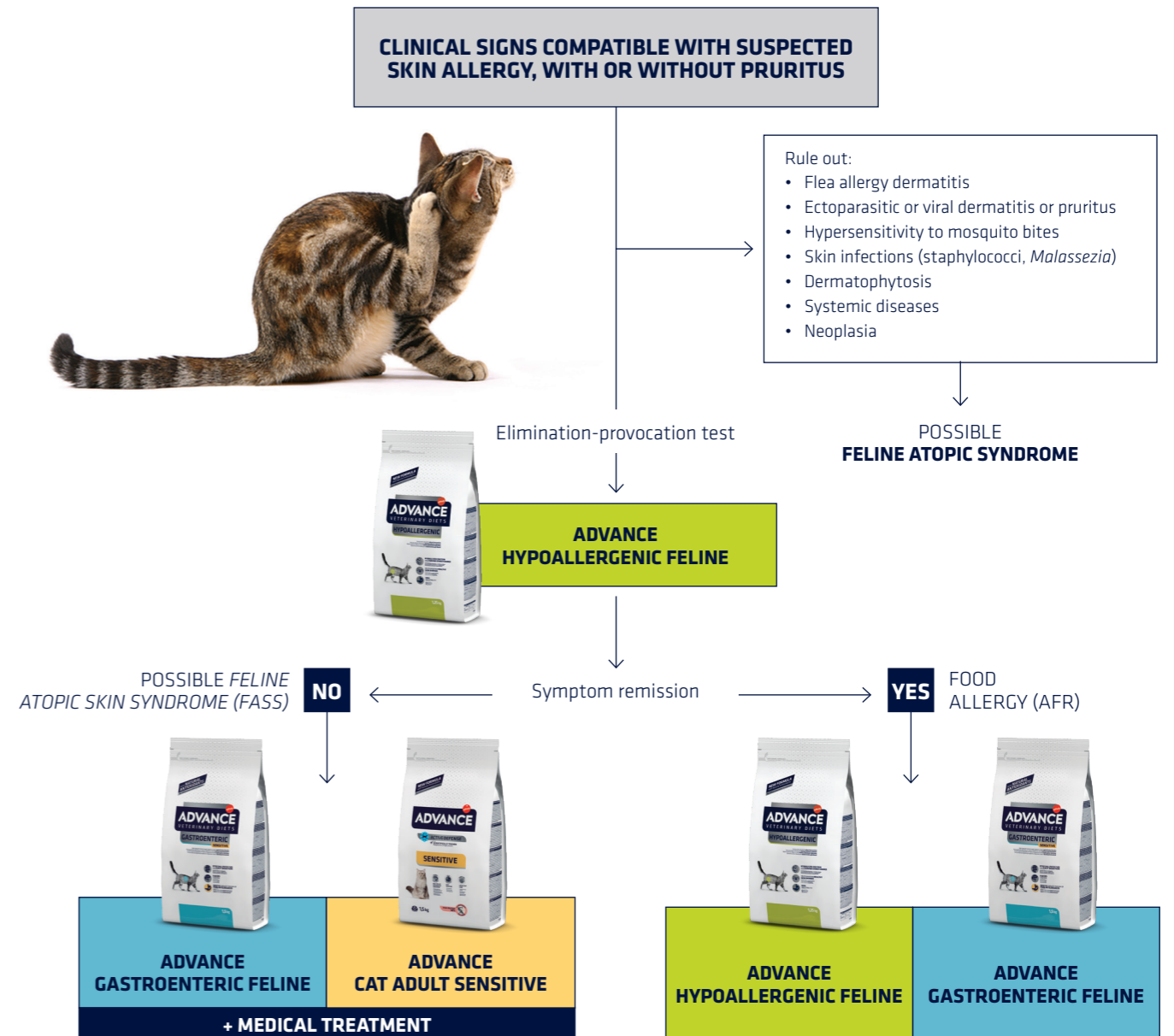
Lastly, it is also important to identify and treat possible skin infections. Staphylococcal and *Malassezia* infec-

tions or overgrowth are common in allergic cats. These infections are associated with skin inflammation due to an allergy and complicate the progress of the disease, increasing the severity of both lesions and pruritus. They could even cause anti-allergy treatments to fail. **Allergy tests are used to identify allergens but are not part of the diagnostic plan**, since they are not considered to be diagnostic. Remember that an allergy diagnosis is clinical, and it is made by ruling out other diseases. These tests, whether intradermal or serological, are appropriate for selecting

the allergens, if allergen-specific immunotherapy (ASIT)* or desensitisation is the chosen treatment.

*ASIT: Allergen-specific immunotherapy.

FIGURE 3. Diagnostic testing with an elimination diet



TREATMENT

The primary objective of treatment is to provide immediate relief for the patient during the diagnostic process.

The therapeutic plan can be divided into short-term and long-term (maintenance) treatment. Certain interventions are considered important in both the short and in the long term, such as continuous use (even in winter) of antiparasitics for the prevention and control of fleas, or the use of antibacterial or antifungal strategies or treatments if secondary infections are identified.

Treatments for *feline atopic skin syndrome* currently include: systemic or topical glucocorticoids, cyclosporine, oclacitinib, ASIT, maropitant, polyunsaturated fatty acids and H1 antihistamines, all of which can be used alone or in combination. Of these, only glucocorticoids, cyclosporine and oclacitinib have been reliably shown to be effective in treating *feline atopic skin syndrome*. ASIT seems to be effective, although information in this regard is still limited (Mueller 2021).

» DIET IN ALLERGIC DERMATITIS

Nutrition plays a major role in the treatment plan, albeit in different

THE MAIN REASONING BEHIND CHOOSING AN ELIMINATION AND PROVOCATION DIET IS TO ENSURE THAT THE PATIENT WILL NOT HAVE HAD ANY PREVIOUS CONTACT WITH OR SENSITISATION TO THE PROTEIN SOURCE CONTAINED IN THE DIET.

ways depending on whether treatment is for an environmental or food allergy. For example, with *feline atopic skin syndrome*, the main objectives are to improve the skin barrier and to reduce the proinflammatory component. These objectives can be met, for instance, by including polyunsaturated fatty acids in the diet. Of greatest interest are the omega-3s, given their antioxidant function.

With food allergies, the focus on nutrition is two-fold. Nutrition can be used not only for diagnostic purposes, but also as long-term treatment, given that in food allergies, managing the disease basically comes down to diet and the avoidance of proteins suspected of causing a clinical manifestation.

Nutrition, when used for diagnosis, mainly involves elimination and provocation diets, the only test currently recommended for ruling out a food allergy. This approach consists of two phases. In the first, the elimination phase, the patient is exclusively given a diet that is very unlikely to trigger an immune response. If the disease does not worsen or relapse, this initial elimination phase is followed by a provocation phase, in which the animal is given their previous diet. With food allergies, patients initially improve during the elimination phase but then the clinical signs recur during the provocation phase.

Several types of diet can be used for this diagnostic test, depending on the source and processing of the proteins they contain. **The main reasoning behind choosing an elimination and provocation diet is to ensure that the patient will not have had any previous contact with, or sensitisation to, the protein source that the diet contains.** In principle, the reasoning is simple, although in practice it is less so on several counts. Firstly, we still do not know the extent of potential cross-reactions which have been identified in vitro (for example between fish and chicken) or in vivo (in 2002, Fujimuru et al. reported the case of a dog with a Japanese cedar allergy that developed an oral allergy syndrome). Moreover, patients can always be found who have had many different diets with a wide variety of protein sources. Another difficulty that can arise is that the dietary history of the animal is unknown, for instance in cats who have been adopted or have changed owner.

It is for these reasons that commercial diets of various types have been developed. These are mainly diets with **novel proteins**, also known as *restricted ingredients*, which are proteins that are not often found in the majority of commercial diets recommended for other purposes or indications. Another specific type of diet is the **'hydrolysed'** diet. These are based on the hydrolysis of proteins to break them down into pep-

tide sizes, thus reducing their molecular weight and allergenicity. The idea behind these diets is that, below a certain molecular size, the proteins are so small that the possibility of being capable of attaching themselves to IgE on the surface of mastocytes and triggering a hypersensitivity response is remote or inexistent. Compared with novel protein diets, extensively hydrolysed diets consisting mainly of proteins with low final molecular weight can be considered truly hypoallergenic (Olivry 2010). It is important, then, that in addition to molecular weight, a high percentage of the proteins is subjected to hydrolysis.

Depending on the **processing method**, diets can be classified as home-prepared, in which cat owners cook or prepare their pets' food, or commercial diets.

Home-prepared diets must be recommended and designed by a veterinary nutritionist in order to avoid nutritional imbalances such as lack of vitamins and minerals, calories, essential fatty acids, proteins and essential amino acids, or carbohydrates. In short, they must be

nutritionally well balanced for the patient and adapted to the animal's age or stage of life.

Commercial diets include the different types mentioned above: novel protein and hydrolysed protein. **In any event, when choosing an elimination diet, it is best to ensure that it is appropriate to the animal's age and clinical history,** which perhaps might include comorbidities. Some diets might be unsuitable for puppies or growing young animals, since their nutritional requirements are different. In other cases, the presence of other concomitant diseases may demand additional specific nutritional requirements. Examples include patients with urinary stones, or metabolic (e.g. liver), cardiac or renal disease.

Another important decision is when to begin an elimination and provocation diet. This depends on the patient: if at the time of consultation they present a severe phenotype, it would be better to wait until lesions are better controlled, making it easier

to evaluate any positive response at the end of the elimination and provocation diet. A recent series of monographs on adverse food reactions concluded that a six-week elimination phase is required to diagnose at least 80% of allergic cats (Olivry 2015). The recommended duration for the provocation phase is usually two weeks. Nevertheless, a protocol on the practice in dogs has been published proposing that the elimination phase can be shortened.



CHARACTERISTICS OF THE ADVANCE VETERINARY DIETS HYPOALLERGENIC FELINE DIET

SELECTED SOURCE OF HYDROLYSED PROTEIN

Diet can be a source of allergens that can interact with the immune system, so it is essential that these are reduced as much as possible in food in order to successfully control adverse food reactions. Proteins are very often the food nutrients that trigger a hypersensitivity reaction.

Food protein hydrolysis is a useful strategy for reducing the risk of reactions in cats that have been sensitised to the intact protein.

AVD Hypoallergenic Feline has been formulated with hydrolysed soy protein as the sole main source of proteins, which has been shown to limit allergic reactions in cats.

After selecting various sources of hydrolysed protein, Advance Veterinary Diets performed immunoblot assays in cats to evaluate the efficacy of the selected soy protein hydrolysis in preventing IgE-type allergic reactions. **Figure 4** shows the molecular weight profile for

native (non-hydrolysed) soy protein as control and the selected hydrolysed soy protein.

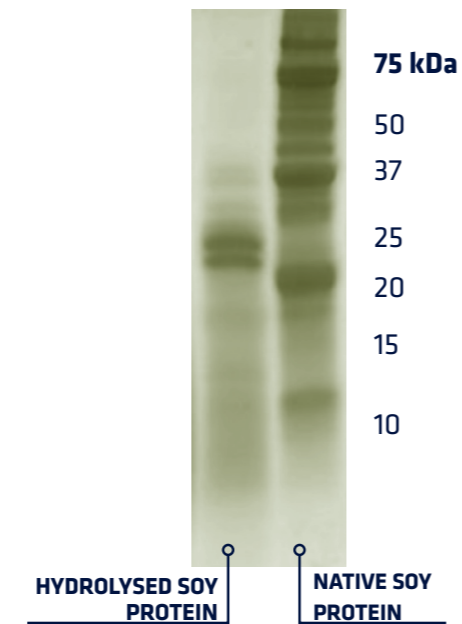
In the study, serum samples from two groups of 10 cats were used:

- **Cats with food sensitivity:** 10 samples from cats with a known history of food allergies (including one cat known to be allergic to soy).
- **Cats in the control group:** 10 samples from cats with no clinical history of food allergies.

The serum samples from the 20 cats (which possibly contained soy-protein-reactive IgE) were incubated with native soy and highly hydrolysed soy protein sources according to immunoblot analytical procedure.

Results show that, although the majority of cats were not clinically diagnosed as being reactive to soy protein, three cats in the control group (30%) and eight cats in the food sensitivity group (80%) showed a mild to intense IgE reaction to native soy protein in the immunoblot test. In contrast, the serum

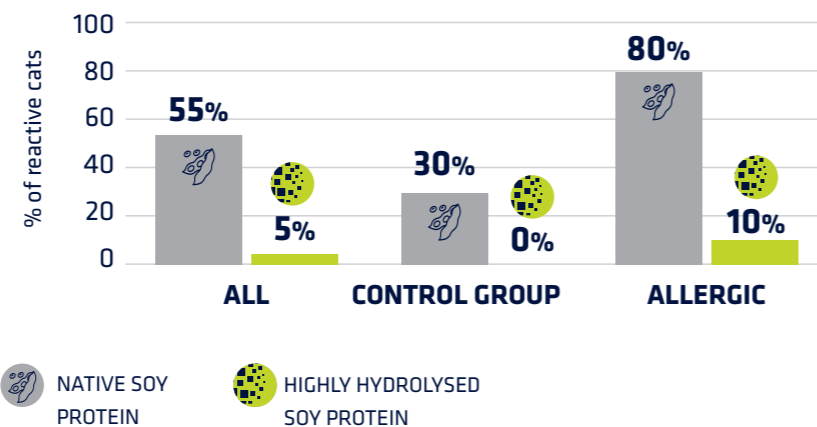
FIGURE 4. Molecular weight profile study



of only one cat in the group of food-sensitive cats showed a slight reaction to highly hydrolysed soy protein (**Figure 5**), which indicates that hydrolysis of soy protein into smaller peptides reduces its allergenic potential.

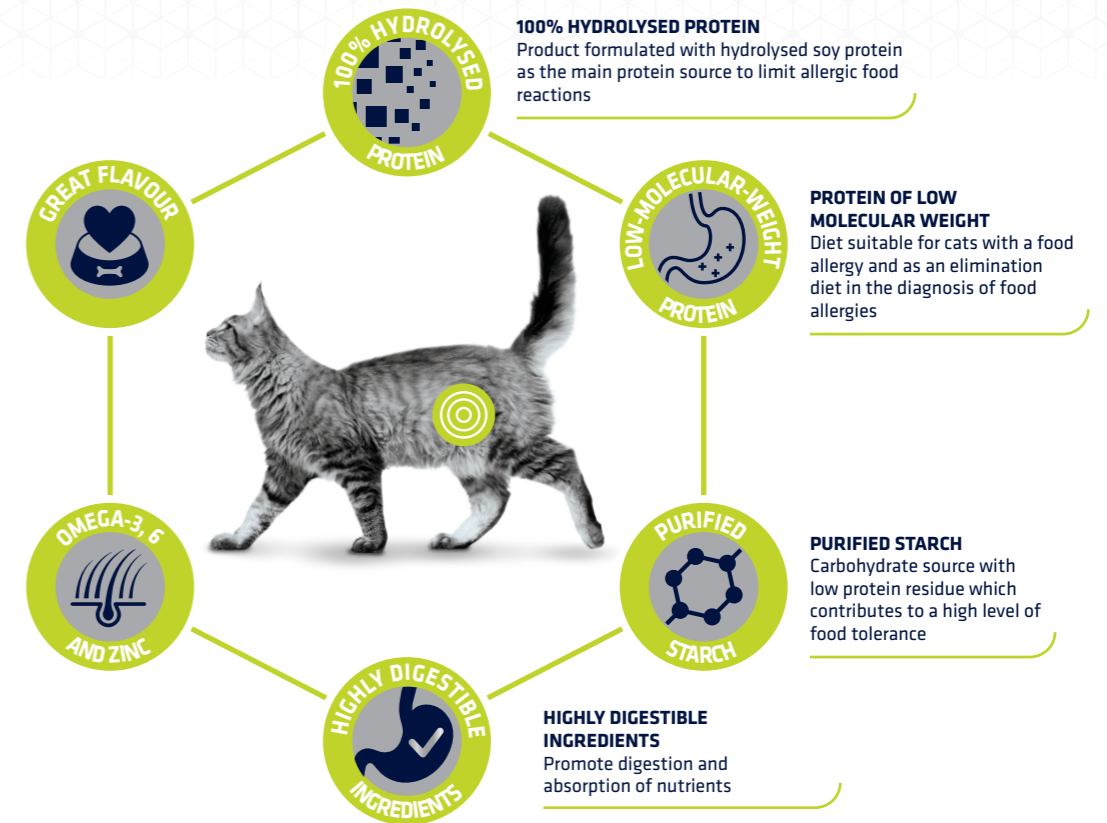
To conclude, reactivity to native soy pro-

FIGURE 5. Percentage of cats (all, control or allergic groups, n=20) displaying reactivity to native or hydrolysed soy protein



HIGH PALATABILITY AND NUTRITIONAL EXCELLENCE
Great taste and balanced diet for a long-term daily diet

ESSENTIAL FATTY ACIDS AND ZINC
Omega-3 and 6 and zinc, which help maintain the skin barrier



tein was detected in 55% of all cats in the study, causing clinical signs of food allergy in some. With the exception of one cat, hydrolysis of soy protein into smaller peptides almost completely reduced its allergenic potential, meaning that it is incapable of inducing an immune response. Based on these results, **hydrolysed soy protein contained in AVD Hypoallergenic Feline can be considered safe for cats with food allergies** (data from Affinity files).

SELECTED SOURCE OF CARBOHYDRATES

The diet also contains purified corn starch as a source of carbohydrate with an insignificant protein residue, which provides energy whilst reducing the risk of causing adverse food reactions.

FATTY ACIDS AND MINERALS

The most common signs of adverse food reactions manifest on the skin.

Therefore, selected sources of protein and starch are important, but other nutrients that help maintain a healthy skin barrier in cats also play a key role.

Omega-3 (e.g. EPA and DHA) and omega-6 fatty acids (e.g. linoleic acid) participate in several skin functions: they act as structural components of the cell membrane, forming the permeable barrier which helps maintain hydration within the skin, while preventing water from penetrating it, and they are precursors of proinflammatory or anti-inflammatory mediators and others.

Cats are unable to synthesise **linoleic acid (omega-6)** and, given their low levels of δ -6-desaturase enzyme activity, they cannot meet their physiological needs for **arachidonic acid** derived from linoleic acid via biosynthetic pathways. Therefore, cats need a diet that provides linoleic acid and arachidonic acid (omega-6), from which other physiologically active metabolites can be derived. Certain conditions, such as dermatitis, can also indicate a need for omega-3 fatty

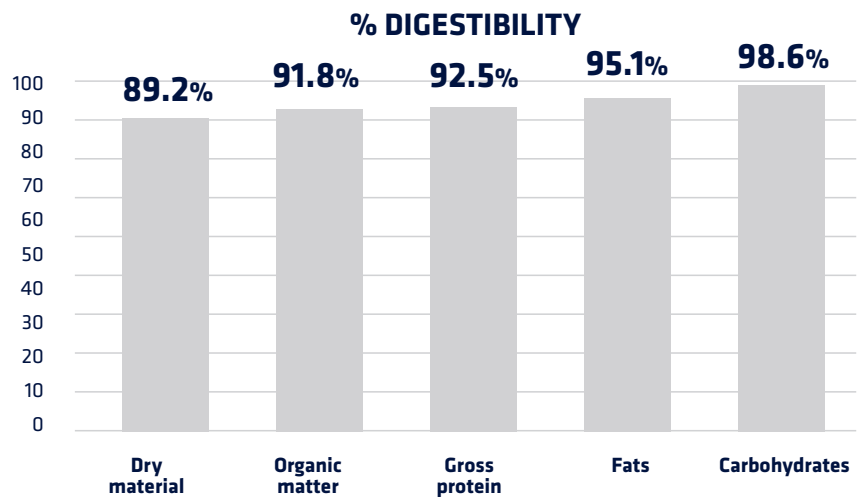
acids in the diet. It is important to provide the optimum ratio of omega-6 to omega-3 to help limit the inflammatory reaction that occurs in cases of dermatitis and other allergic reactions. In terms of dry matter, **AVD Hypoallergenic Feline** contains on average 2.9% omega-6 fatty acids and 0.7% omega-3 fatty acids (thus maintaining the omega-6/omega-3 ratio below 5).

Zinc is an essential trace element required in very small amounts, but it is vital because it helps preserve the integrity of the skin and mucous membranes. It acts as a cofactor in numerous enzymatic pathways and is particularly important for rapid cell division, including skin cells. Zinc is also crucial for fatty acid biosynthesis, participates in both the inflammatory and the immune systems, and plays a part in vitamin A metabolism. **AVD Hypoallergenic Feline contains a zinc supplement at higher levels than those recommended to ensure a complete, balanced diet.**

HIGHLY DIGESTIBLE DIET

Adverse food reactions in cats can also manifest clinically as digestive symptoms, such as vomiting or diarrhoea, together with anorexia, weight loss, flatulence, abdominal swelling (Bryan & Frank, 2010; Guilford et al., 2001) and inflammatory intestinal disease (IID). These symptoms show that adverse food reactions impair the gastrointestinal tract, jeopardising digestion and the absorption of nutrients. A highly digestible diet with hydrolysed protein is therefore key to controlling adverse food reactions. This type of diet could also be useful for feline chronic enteropathies of unknown aetiology which produce similar symptoms (Kathrani, 2020). **AVD Hypoallergenic Feline has been formulated with top-quality, highly digestible ingredients to create a first-class product with excellent nutrient digestibility (Figure 6).**

FIGURE 6. *In vivo* digestibility values for AVD Hypoallergenic Feline



REFERENCES

Bryan J, Frank LA. Food allergy in the cat: a diagnosis by elimination. *J Feline Med Surg.* 2010 Nov;12(11):861-6. doi: 10.1016/j.jfms.2010.09.005.

Diesel A. Feline Atopic Syndrome: Epidemiology and Clinical Presentation. In: *Feline Dermatology*. Eds. Chiara Noli, Silvia Colombo. Springer Nature. Switzerland AG, 2020.

Fujimura M, Ohmori K, Masuda K, Tsujimoto H, Sakaguchi M. Oral allergy syndrome induced by tomato in a dog with Japanese cedar (*Cryptomeria japonica*) pollinosis. *J Vet Med Sci.* 2002 Nov;64(11):1069-70. doi: 10.1292/jvms.64.1069.

Guilford WG, Jones BR, Markwell PJ, Arthur DG, Collett MG, Harte JG. Food Sensitivity in Cats with Chronic Idiopathic Gastrointestinal Problems. *J Vet Intern Med* 2001;15:7-13

Halliwell R, Banovic F, Mueller RS, Olivry T. Immunopathogenesis of the feline atopic syndrome. *Vet Dermatol.* 2021 Feb;32(1):13-e4. doi: 10.1111/vde.12928. PMID: 33470018.

Halliwell R, Pucheu-Haston CM, Olivry T, et al. Feline allergic diseases: introduction and proposed nomenclature. *Vet Dermatol.* 2021 Feb;32(1):8-e2. doi: 10.1111/vde.12899. PMID: 33470016.

Kathrani A, Church DB, Brodbelt DC, Pegram C, O'Neill DG. The use of hydrolysed diets for vomiting and/or diarrhoea in cats in primary veterinary practice. *Journal of Small Animal Practice* (2020) 61, 723-731 DOI: 10.1111/jsap.13214

Moriello K, Halliwell REW. Promise made, promise kept: it is the cat's turn. *Vet Dermatol.* 2021 Feb;32(1):5-6.

Mueller RS, Nuttall T, Prost C, Schulz B, Bizikova P. Treatment of the feline atopic syndrome - a systematic review. *Vet Dermatol.* 2021 Feb;32(1):43-e8. doi: 10.1111/vde.12933. PMID: 33470011. doi: 10.1111/vde.12935. PMID: 33470017.

Older CE, Diesel AB, Starks JM, Lawhon SD, Rodrigues Hoffmann A. Characterization of staphylococcal communities on healthy and allergic feline skin. *Vet Dermatol.* 2021 Feb;32(1):61-e10. doi: 10.1111/vde.12885. Epub

2020 Sep 29. PMID: 32991044.

Olivry T, Bizikova P. A systematic review of the evidence of reduced allergenicity and clinical benefit of food hydrolysates in dogs with cutaneous adverse food reactions. *Vet Dermatol.* 2010 Feb;21(1):32-41. doi: 10.1111/j.1365-3164.2009.00761.x

Olivry T, Mueller RS, Prélaud P. Critically appraised topic on adverse food reactions of companion animals (1): duration of elimination diets. *BMC Vet Res.* 2015 Aug 28;11:225. doi: 10.1186/s12917-015-0541-3.

Santoro D, Pucheu-Haston CM, Prost C, Mueller RS, Jackson H. Clinical signs and diagnosis of feline atopic syndrome: detailed guidelines for a correct diagnosis. *Vet Dermatol.* 2021 Feb;32(1):26-e6.

Vargo C, Gogal R, Barber J, Austel M, Banovic F. Characterisation of the serum cytokine profile in feline atopic skin syndrome. *Vet Dermatol.* 2021 Oct;32(5):485-e133. doi: 10.1111/vde.12994. Epub 2021 Jun 27. PMID: 34180094.